




(<https://debug.globalseafood.org>).



Health &  
Welfare

## AHPND is a chronic disease in Pacific white shrimp from Latin America

17 August 2020

By Luis Fernando Aranguren Caro, Ph.D. , Hung N. Mai, Ph.D. , Brenda Noble, B.Sc. and Arun K. Dhar, Ph.D.

### Study is first to report a 'lingering phase' of this important disease



Shrimp from one of the challenge studies. Animal on the bottom is affected by AHPND while the one top is normal. Note coloration of the hepatopancreas in each animal.

Since 2009, Acute Hepatopancreatic Necrosis Disease (AHPND) progressively spread as an epidemic, devastating shrimp production across much of the shrimp farming regions in Asia and eventually the Western Hemisphere, including an outbreak identified on a farm in the United States.

Previous estimates of the cumulative economic impact of AHPND have ranged from \$8 billion (U.S.) for Asia and \$4 billion for America. However, in recent years, shrimp production has improved in countries previously hard hit by AHPND, as farmers have tested, improved and adapted husbandry practices that mitigate important environmental risk factors; and as knowledge of the molecular features, detection methods and options for AHPND management have evolved.



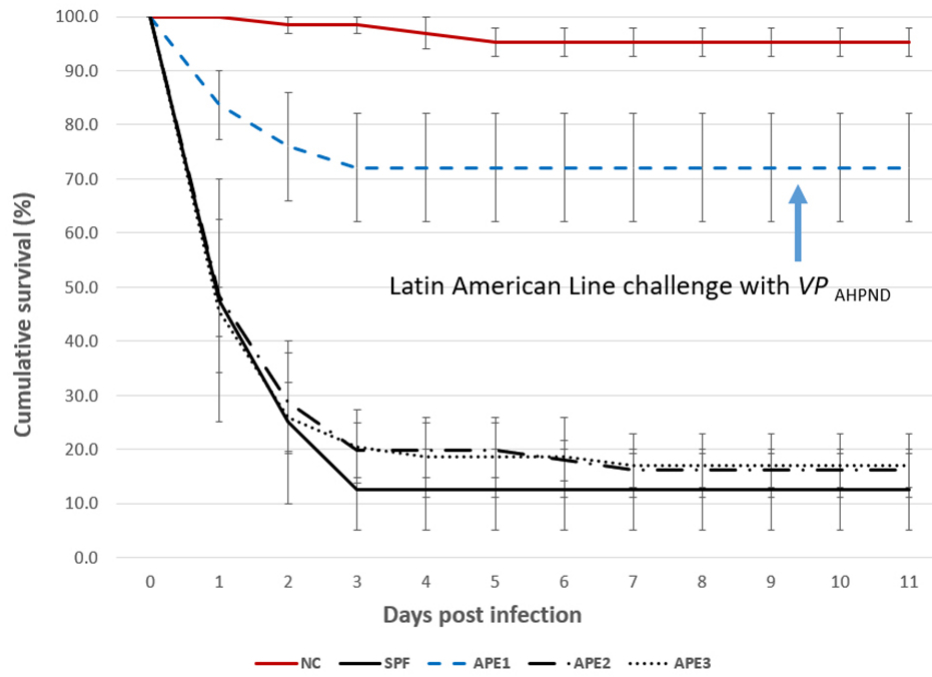


Fig. 1: Trial I: Cumulative survival for four *P. vannamei* lines exposed to  $VP_{AHPND}$  ( $1 \times 10^5$  CFU per ml). Negative control (NC) for APE1-3 (red solid line), APE1 (dashed blue line), APE2 (dash-dot line), APE3 (dotted line) and SPF (black solid line). Data shown are the average of three (APE1, 2, 3) or two (SPF) replicates. Error bars represent the 95 percent confidence interval of the data set.

## PCR

Eleven samples of hepatopancreas from dead shrimp in the  $VP_{AHPND}$  Trial I were collected and pooled per line/tank and tested by a duplex PCR [a Polymerase Chain Reaction test that simultaneously detects and differentiates two different genes, *pirA* and *pirB* encoding the binary toxin] assay to detect *pirA* and *pirB*. All the pooled samples were positive for both *pirA* and *pirB* and the bands that amplify the region of 284 bp and 392 bp were clearly observed. Samples from the unexposed lines (negative controls) were pooled per tanks and analyzed by duplex PCR, with negative results in all the cases.

## Histopathology

The histopathology of the SPF population in Trial II is presented in Figs. 2 and 3. The Davidson-fixed [a fixative solution to preserve tissue samples] shrimp from the healthy, negative control shrimp in the SPF line displayed normal structure of tubules and epithelial cells in the hepatopancreas, including high levels of lipid droplets (R-cells), secretory vacuoles (B-cells) and absence of AHPND (Fig. 2A). In contrast, SPF shrimp fixed in the first and second day post infection (d.p.i) displayed lesions typical of  $VP_{AHPND}$  in the acute phase, including a multifocal necrosis [dead cells in several locations] and massive sloughing of HP tubule epithelial cells in the medial region of the hepatopancreas and progressing outward to the distal region. Very low levels of B-cells and R-cells were observed (G0-G1) and hemocytic infiltration surrounding necrotic tubules was common. At this point, bacterial colonization was not observed (Fig. 2B).

Fig. 2: H&E (Mayer–Bennet hematoxylin and eosin-phloxine) histology of VPAHPND-infected SPF shrimp at 24 hpi-6 dpi: (A) *P. vannamei* from the negative control tank (B) Acute phase of AHPND infection (C) terminal phase of AHPND infection (D) Chronic phase of AHPND infection. Scale bars = 100 $\mu$ . Photos B through D represent specific-pathogen-free line shrimp.

Fig. 3: H&E (Mayer–Bennet hematoxylin and eosin-phloxine) histology of VPAHPND-infected APE shrimp at 24 hpi-6 dpi: (A) *P. vannamei* from the negative control tank (B) Acute phase of AHPND infection (C) terminal phase of AHPND infection (D) Chronic phase of AHPND infection. (E) Possible AHPND G-trace. (F) Line 1 survivor shrimp challenged with VPAHPND sampled at 6 dpi. Scale bars = 100  $\mu$ m. Photos B through F represent APE lines shrimp.

Some of the other SPF shrimp analyzed displayed the typical  $VP_{AHPND}$  terminal phase characterized by necrosis and sloughing of HP tubule epithelial cells to (Fig. 2C) massive bacterial presence and host inflammatory response between and within HP tubules. Interestingly, some survivors at 7 d.p.i showed only a few tubules with epithelial necrosis accompanied by bacteria and inflammation, which resembles a septic hepatopancreatic necrosis (SHPN) (Fig. 2D), which has not previously been described as a type of lesion in the case definition for AHPND (Table 1).

### Aranguren, LatAm Shrimp AHPND, Table 1

Tank No.	Shrimp line	No. shrimp	Treatment	Immersion challenge dose of AHPND-VP (CFU/ml)
A4	APE2	22	AHPND Negative control	Unexposed
A5	APE3	19	AHPND Negative control	Unexposed
A6	APE1	25	AHPND Negative control	Unexposed
L1	SPF	20	AHPND Positive control	$1 \times 10^5$
L2	SPF	20	AHPND Positive control	$1 \times 10^5$
D1	APE2	18	AHPND	$1 \times 10^5$
D2	APE2	19	AHPND	$1 \times 10^5$
D3	APE2	19	AHPND	$1 \times 10^5$
D4	APE3	19	AHPND	$1 \times 10^5$
D5	APE3	21	AHPND	$1 \times 10^5$

D6	APE3	17	AHPND	$1 \times 10^5$
5A	APE1	25	AHPND	$1 \times 10^5$
5B	APE1	28	AHPND	$1 \times 10^5$
5C	APE1	25	AHPND	$1 \times 10^5$

Table 1. Description of the shrimp lines and treatments utilized in the VPAHPND challenge, Trial I.

On the other hand, the histopathology of shrimp representing the Latin American lines (APE1, APE2 and APE3) is presented in Fig. 3. Fig. 3A shows the HP histology of a healthy shrimp from the APE negative control tank. The histology was similar to the normal HP histology in the animals from the SPF line. Figs. 3B and 3C, respectively, are histology examples of the typical acute and terminal phase of AHPND and Fig. 3D is an example of the appearance of chronic phase AHPND histology for a survivor shrimp after 6 d.p.i. Similar chronic, histopathology lesions were observed in shrimp in the SPF line. The granulomatous response in the HP tubules would be an indicator of an inflammatory response at a more advanced stage of maturity in the chronic phase in AHPND-affected shrimp. Unlike the previous set of figures, Fig. 3E presents a suspected case of AHPND (G-trace) with focal necrosis and sloughing of tubules epithelial cells in the medial portion of HP. Two survivors from APE1 had no histopathological lesions indicative of AHPND, which suggest a possible tolerance/resistance to AHPND infection (Fig. 3F).

## Bacteriology

Fig. 4 summarizes the HPC for the HP of control and  $VP_{AHPND}$  challenged shrimp at 24 h.p.i. For the negative control group, the highest mean count was recorded for APE1 ( $2.22 \times 10^7$  CFU per gram HP). In contrast, the lowest mean control count was for the SPF line ( $1.05 \times 10^4$  CFU per gram HP). The 24 h.p.i.  $VP_{AHPND}$  challenge tank samples showed the HPC increased significantly ( $P < 0.05$ ) between control and treatment shrimp for the APE2, APE3 and SPF lines, with the largest differential mean count:  $3.70 \times 10^7$  CFU per gram HP for the SPF line,  $\sim 10^3$  times higher than the mean negative control count for this line ( $1.05 \times 10^4$  CFU per gram HP). The APE1 line had little change in mean CFU per gram HP between the negative control ( $2.20 \times 10^7$  CFU per gram HP) and the  $VP_{AHPND}$  challenged cohort samples ( $2.13 \times 10^7$  CFU per gram HP) in the study.

Fig. 4: Comparison of the heterotrophic plate count (HPC) determined in CFU per gram HP in four lines of shrimp exposed with VPAHPND at 24 h.p.i. NTC: Negative control; AHPND: challenge with VPAHPND. Data represent the mean  $\pm$  SE.

## Discussion

In this study, four *P. vannamei* shrimp lines, including an SPF line and three Latin American shrimp lines, were challenged via immersion with a virulent strain of  $VP_{AHPND}$  using a bacterial cell density of  $\sim 1 \times 10^5$  CFU per ml. One of the Latin American lines (APE1 line) displayed significantly improved survival as compared to the APE2, APE3 and the SPF lines to  $VP_{AHPND}$  challenge under laboratory experimental conditions examined.

AHPND acute and terminal phase lesions were recorded in moribund shrimp in the two trials. In Trial I, the survivor shrimp (6 d.p.i) also showed a histology change and septic hepatopancreatic necrosis (SHPN) (Figs. 2D, 3C & 3D). It is interesting to note that SHPN was not included in the pathology description of AHPND (Lightner & Flegel 2012 ([applewebdata://4C9D4314-C0E4-43B2-8D8C-91656D55E9FA#\\_ENREF\\_18](https://applewebdata://4C9D4314-C0E4-43B2-8D8C-91656D55E9FA#_ENREF_18)), OIE 2018 ([applewebdata://4C9D4314-C0E4-43B2-8D8C-91656D55E9FA#\\_ENREF\\_22](https://applewebdata://4C9D4314-C0E4-43B2-8D8C-91656D55E9FA#_ENREF_22))) probably because during the first years of the infection in Southeast Asia, the mortality was close to a 100 percent in most of the cases.

To our knowledge, this is the first record of SHPN in  $VP_{AHPND}$  infected shrimp. Other chronic, hepatopancreas changes observed were granulomata, focal to multifocal melanization of HP tubules, low cytoplasmic lipid and atrophy of tubule epithelial cells. One survivor from the APE group had mild tubule epithelial necrosis (Fig. 3E) and in another specimen no AHPND lesions were observed at all (Fig 3F). These histological features could indicate tolerance/resistance in shrimp from APE 1 line.

In Trial II, the HPC in hepatopancreas increased at 24 h.p.i. in the  $VP_{AHPND}$  treatments when compared to the negative control tank for the APE2, APE3 and the SPF lines. The CFU per gram HP control counts in the APE2, APE3 and SPF lines ranged between  $\sim 10^4$  and  $\sim 10^6$ ; whereas for the APE1 line the CFU per gram HP were significantly higher (mean =  $2.20 \times 10^7$  grams HP). The highest control to challenge differential was 1:  $3.01 \times 10^3$  for the SPF line; whereas for the

high survival APE1 line, the mean difference was 1.04:1, essentially unchanged between the control and the  $VP_{AHPND}$  challenged shrimp.

Following the  $VP_{AHPND}$  challenge, the mean CFU per gram HP increased for lines 2, 3 and 4. The mean HPC was  $1.7 \times 10^7$  CFU per gram HP (range:  $9.52 \times 10^4$  to  $1.0^5 \times 10^8$  CFU per gram HP). Although the bacterial load was quite variable among different animals, the CFU mean was consistent with previous challenge test studies we have carried out at the APL. In our data, the hepatopancreas bacterial count which was comprised of the  $VP_{AHPND}$  as well as the natural bacterial flora likely increased in response to the increased availability of nutrients (necrotic cellular debris and exposed tubule basal membrane) in the affected HPs.

In this study, improved survival was associated with very high hepatopancreas HPC prior to the  $VP_{AHPND}$  challenge in the APE1 line. Perhaps an initial high bacteria biomass in the stomach/hepatopancreas had a negative influence on *V. parahaemolyticus* colonization and/or replication, either through direct bacteria to bacteria antagonism and/or the high bacteria load was associated with greater activity of the shrimps' innate immune system, thus giving the individual APE1 animals an increased host tolerance to AHPND. In any case, the reason(s) behind the higher survival recorded for APE1 would be worthwhile to explore further.

Despite the strong evidence of the presence of AHPND in Latin America, farmed shrimp production in this region has grown continuously during the last 10 years (GOAL 2019, FAO 2018). The chronic mortalities caused by AHPND at the farm level in grow-out ponds were similar to the chronic mortalities reported in our study through a  $VP_{AHPND}$  challenge test of the shrimp lines used in Latin America. In order to explain this AHPND resistance/tolerance, it is important to look at the history of the shrimp industry in Latin America. Since the early days, the vast majorities of farms in Latin America have utilized a "live with the pathogens" approach, referred to as All Pathogens Exposed (APE).

The shrimp industry in Latin American countries has been exposed to several pathogens during the last 30 years, including viral pathogens such as Taura Syndrome Virus (TSV) from 1992 to 1995 and White Spot Syndrome Virus (WSSV) since 1999. With no other options, some of the major producers initiated a program to select the survivors, initially from TSV-infected ponds and later on from WSSV-infected ponds.

In the mid-term, the shrimp industry started seeing some recovery in their ponds previously hit by these viral pathogens. From 2010-2019, the shrimp industry in Ecuador – by far the largest shrimp producer in the Americas – enjoyed increased pond survival and production despite the presence of these pathogens in the culture ponds.

During the TSV and WSSV selection process by the shrimp farmers, some other diseases including bacterial diseases have been present at the farm level – including SHPN and seagull syndrome – and some at the hatchery level (including bioluminescent *V. harveyi* and Bolitas syndrome), which might suggest that these APE populations have been exposed to several bacterial pathogens and have acquired some tolerance to multiple pathogens simultaneously. Also, shrimp in Colombia selected for resistance to TSV indirectly acquired resistance to Necrotizing Hepatopancreatitis (NHP), an endemic disease present in the broodstock ponds at that time.

Fig. 5. Evolution of the pathology of AHPND in Latin America, with microphotographs of the tubules of hepatopancreas of affected animals, from the acute phase (1), to the terminal phase, to the chronic phase, and eventually to the tolerant/resistant line.

We believe that similar developments could have occurred with these Latin American stocks that encountered *Vibrio* infections during the farm culture conditions. In Latin America shrimp farms, AHPND does not lead to the acute mortalities that occur in Southeast Asia farms. Our study is the first report of a new phase of infection of AHPND, a chronic phase based on experimental AHPND-challenge trials we conducted using shrimp lines from Latin America. Our results explain in part why the shrimp industry in various Latin American countries have continue to expand regardless of the presence of AHPND. In addition, our results show that the biology and pathology of AHPND resistant/tolerant shrimp appear to be quite unique in this Latin American shrimp population.

## Perspectives

In summary, we have described bioassay challenge results that identified one of three Latin American lines that displayed improved (~70 percent) survival to AHPND challenge as compared to the two other APE and the SPF positive control lines.


The difference in survival could be attributed to either elevated bacteria recorded in the HP of individual APE1 animals and/or yet unknown attribute to tolerance to AHPND in this line when compared to the three other lines evaluated in the two trials.

Additional comparative studies are planned to learn more about qualitative and quantitative bacteriology in hepatopancreas samples collected in Trial II.

References available from the corresponding author.

## Authors

---



**LUIS FERNANDO ARANGUREN CARO, PH.D.**

Corresponding author  
School of Animal and Comparative Biomedical Sciences  
University of Arizona, 1117 E. Lowell Street  
Tucson, Arizona 85721 USA

[lfarangu@email.arizona.edu](mailto:lfarangu@email.arizona.edu) (<mailto:lfarangu@email.arizona.edu>)



**HUNG N. MAI, PH.D.**

School of Animal and Comparative Biomedical Sciences  
University of Arizona, 1117 E. Lowell Street  
Tucson, Arizona 85721 USA



**BRENDA NOBLE, B.SC.**

School of Animal and Comparative Biomedical Sciences  
University of Arizona, 1117 E. Lowell Street  
Tucson, Arizona 85721 USA



**ARUN K. DHAR, PH.D.**

School of Animal and Comparative Biomedical Sciences  
University of Arizona, 1117 E. Lowell Street  
Tucson, Arizona 85721 USA

Copyright © 2023 Global Seafood Alliance

All rights reserved.