




ALLIANCE™

(<https://debug.globalseafood.org>).



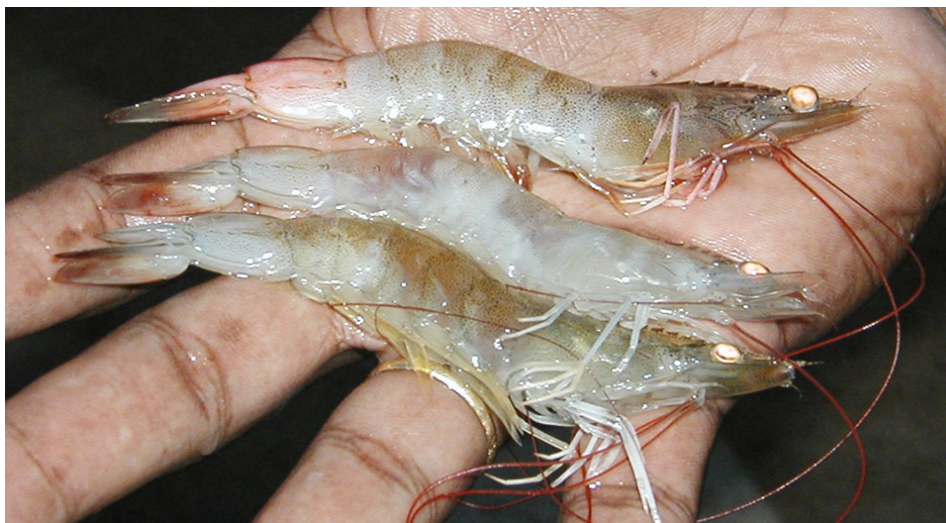 Health & Welfare

Infectious myonecrosis: New disease in Pacific white shrimp

1 October 2004

By D.V. Lightner, Ph.D. , C.R. Pantoja, Ph.D. , B.T. Poulos , K.F.J. Tang , R.M. Redman , T. Pasos-de-Andrade and J.R. Bonami

First discovered in Brazil in 2002



Subadult shrimp display clinical signs of IMN in extensive white necrotic areas of the skeletal muscle in their abdomens. In some shrimp, the necrotic muscle reddens.

Infectious myonecrosis (IMN) was recently identified in cultured Pacific white shrimp (*Litopenaeus vannamei*) in northeastern Brazil. IMN presents as a disease with an acute onset of gross signs and elevated mortalities, but progresses with a chronic course accompanied by persistent low-level mortalities.

The disease was first recognized by shrimp farmers as a distinctive phenomenon in September 2002 at a shrimp farm in Pernambuco in the state of Piauí. The infectious nature of IMN was experimentally demonstrated in 2003, with the causative agent identified as a new virus.

To date, IMN appears to be limited to northeastern Brazil. However, shrimp with similar gross signs have also been reported in other countries where *L. vannamei* are cultured.

Mortalities

IMN affects postlarvae, juveniles, and subadult pond-reared stocks of *L. vannamei*. Losses due to IMN in 2003 were estimated at approximately U.S. \$20 million by Nunes and coauthors in the May/June 2004 *Panorama da Aqüicultura*. Outbreaks of the disease seem to be associated with environmental and physical stresses such as extremes in salinity and temperature, collection by cast net, and possibly the use of low-quality feeds.

Clinical signs and histopathology

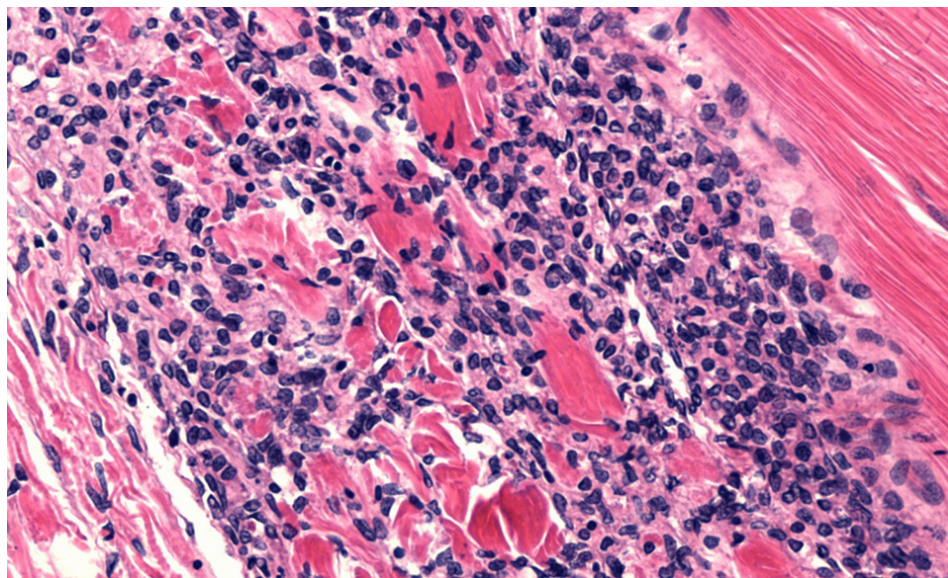


Fig. 1: Myonecrosis due to IMN accompanied by hemocytic infiltration and fibrosis. Normal skeletal muscle can be seen in the upper right corner. Magnification: 50x.

Affected shrimp present focal to extensive white necrotic areas in striated muscles, especially the distal abdominal segments and tail fan, which can become necrotic and reddened in some individual shrimp. Since the progression of the disease is relatively slow, but with persistent mortalities, feed-conversion rates tend to increase and add to economic losses.

By

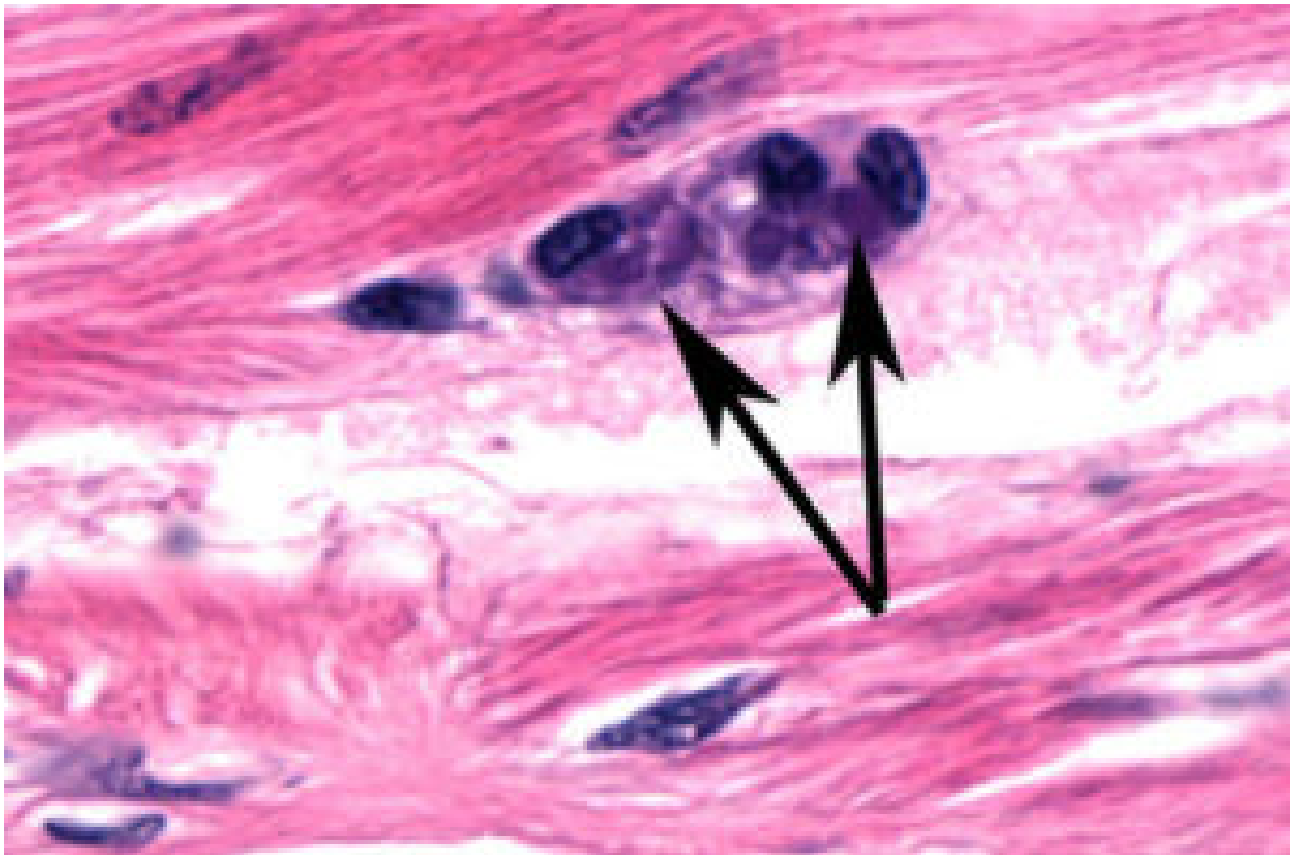

Fig. 2: Basophilic inclusion bodies are evident in these groups of muscle cells. Magnification: 150x.

histopathology, shrimp with acute-phase IMN present lesions with coagulative muscle necrosis, often with edema. In shrimp recovering from acute IMN or those in its more chronic phase, the necrosis appears to progress from coagulative to liquefactive. This progression is accompanied by hemocytic infiltration and fibrosis (Fig. 1).

Significant spheroid formation is typically present in the lymphoid organ, and ectopic lymphoid organ spheroids are often found in the hemocoel and loose connective tissues, especially in the heart lumen and adjacent to antennal gland tubules. In some histological preparations, perinuclear pale to darkly basophilic inclusion bodies are evident in muscle cells (Fig. 2), connective tissue cells, hemocytes, and cells that comprise lymphoid organ spheroids.

Identification, diagnostic methods

A 40-nm-diameter spherical virus has been isolated from naturally infected shrimp with the disease. The virus has been partially characterized, and portions of its nucleic acid (RNA) genome have been cloned and sequenced.

Molecular probes and reverse transcription polymerase chain reaction (RT-PCR) methods for IMN diagnosis have been developed and will be reported. A commercial RT-PCR kit for IMN will likely be on the market in late 2004 or early 2005.

(Editor's Note: This article was originally published in the October 2004 print edition of the Global Aquaculture Advocate.)

Authors



D.V. LIGHTNER, PH.D.

University of Arizona
Aquaculture Pathology Group
Tucson, Arizona 85721 USA

dvl@u.arizona.edu (<mailto:dvl@u.arizona.edu>).



C.R. PANTOJA, PH.D.

University of Arizona
Aquaculture Pathology Group
Tucson, Arizona 85721 USA



B.T. POULOS

University of Arizona
Aquaculture Pathology Group
Tucson, Arizona 85721 USA



K.F.J. TANG

University of Arizona
Aquaculture Pathology Group
Tucson, Arizona 85721 USA



R.M. REDMAN

University of Arizona
Aquaculture Pathology Group
Tucson, Arizona 85721 USA



T. PASOS-DE-ANDRADE

University of Arizona
Aquaculture Pathology Group
Tucson, Arizona 85721 USA



J.R. BONAMI

University of Arizona
Aquaculture Pathology Group
Tucson, Arizona 85721 USA

Copyright © 2023 Global Seafood Alliance

All rights reserved.